

I. Ghedbane<sup>1</sup>  
M. Habbeche<sup>1</sup>  
N. Oufriha<sup>1</sup>  
D. Mouas<sup>1</sup>  
M. Benmouhoub<sup>2</sup>  
S. E. Bouyoucef<sup>1</sup>

<sup>1</sup>Department of Nuclear Medicine,  
CHU Bab El Oued, 16000 Algiers,  
Algeria.

<sup>2</sup>Clinic of Otolaryngology, Setif 19000,  
Algeria

**Correspondencia:**

Professor SE Bouyoucef,

Head of Department of Nuclear Medicine, CHU  
Bab El Oued, 16000, Algiers, Algeria  
Tel:++21321964596 Fax:++21321965101  
e-mail:bsenucmed@yahoo.fr  
No disclosure and no conflict of interest

**Cita / Reference:**

Ghedbane, I. Aggressive form of  
thyroglossal duct cyst carcinoma:  
Role of ablative dose of Iodine-131.  
Alasbimn Journal 12 (47): January  
2010. Article N° AJ47-8  
<http://www.alasbimnjournal.c/>

**Aggressive form of thyroglossal duct cyst carcinoma: Role of ablative dose of Iodine-131.  
AJ47-8**

**Abstract**

Ectopic thyroid tissue carcinoma is very rare and has usually good prognosis. It could arise in 1% of thyroglossal duct cysts (TDC), the most common nonodontogenic cysts that occur in the neck, which results from a failure in obliterating the embryogenic duct produced during thyroid migration. TDC is most often diagnosed during the childhood but may be discovered later in adult age. In most of the cases reported in the literature, thyroid carcinoma arising in the TDC is limited to the cyst without local extension and its efficient treatment consist of the surgical removal of the cyst by Sistrunk's operation. However, some controversies remain regarding the indication of total thyroidectomy when thyroid investigations are normal. Cases of aggressive thyroid carcinomas of the TDC with metastatic cervical lymph nodes are exceptional, mainly when histological findings of the thyroid gland are normal. We report a case of an aggressive form of a thyroglossal duct cyst carcinoma complicated with several infiltrated cervical lymph nodes but normal thyroid gland. The therapeutic strategy adopted in this case shows the decisive role of the post-operative ablative dose of Iodine-131 both for treatment and staging of aggressive form of thyroid carcinoma arising in thyroglossal duct cyst.

**Key words**

Thyroglossal duct carcinoma, Thyroid carcinoma, Cervical lymphadenectomy, Ablative dose of Iodine 131.

**Introduction**

Ectopic thyroid tissue carcinoma is very rare and only 1% of thyroglossal duct cysts (TDC) are suspect of thyroid malignancy <sup>(1)</sup>. Papillary carcinoma is the most frequent histological type (more than 75%) arising in a TDC and has a good prognosis, similar to that of papillary carcinoma of the thyroid gland <sup>(2)</sup>. Most of the cases of thyroglossal duct carcinoma occur within the cyst and do not produce any local infiltration. It seldom happens that a thyroglossal duct carcinoma is associated to a thyroid gland carcinoma, more rarely with lymph node infiltration <sup>(3)</sup>. However, thyroid carcinoma arising in TDC with infiltrated cervical lymph nodes but normal thyroid gland is exceptional. This clinical case shows an aggressive form of a TDC carcinoma combined with multiple infiltrated cervical lymph nodes and a normal thyroid gland. The therapeutic strategy is discussed and the impact of post operative ablative dose of Iodine-131 is highlighted.

**Clinical case**

A 26 year-old woman presented with complaints of a painless midline swelling over the anterior aspect of the neck, which had been growing slowly over the last 4 years to reach the size of a small egg. She did not have antecedents of cervical irradiation or other malformation. Clinical examination found a midline neck swelling of 2 cm diameter moving with deglutition and protrusion of the tongue, and a left cervical lymph node. Palpation of thyroid gland was normal. Cervical ultrasonography (US) showed a TDC of 3 cm at the level of hyoid bone with a lymph node anterior to the jugular vein. Thyroid gland was normal as well as the thyroid function tests. Neck computed tomography (CT) showed a midline multicystic lesion with small foci of irregular calcification in the upper left part of hyoid bone above the isthmus of the thyroid gland. Cytopathological examination of fine needle aspiration was not conclusive. The cyst was removed by Sistrunk's operation. Negative margins were achieved and there were no local signs of invasion of the tissue surrounding the cyst. Gross examination of specimen showed a TDC partially filled by a solid brownish tissue. Histological examination revealed papillary carcinoma in several sites of the thyroid tissue of the TDC located mainly in the different walls of the cyst. Pathology findings were consistent with an aggressive form of thyroglossal duct thyroid carcinoma. Given the suspicion of lymph node invasion, a decision of enlarged thyroidectomy was taken. Patient underwent a second surgical procedure consisting of total thyroidectomy and central and left cervical lymphadenectomy. Histological sections of thyroid gland showed normal findings but there was evidence of metastasis of papillary thyroid carcinoma in 2 of 15 removed lymph nodes. Three months later, the patient received an ablative dose 3,7 GBq of Iodine-131 under intrinsic stimulation (TSH>50uU/ml). The post-therapy scan showed two thyroid remnants and a site of high cervical uptake compatible with a submaxilar lymph node not previously seen by US (Fig 1). Thyroglobulin serum measurement was 5ng/ml with negative thyroglobulin antibodies (TgAb). The patient was given suppressive therapy with a daily thyroxin dose of 175 ug with satisfactory regular follow up under thyroxin (TSH <0.1uU/ml and undetectable thyroglobulin). At one year, the diagnostic total body scan with 185 MBq of <sup>131</sup>I under intrinsic stimulation (TSH>50uU/ml) was normal (Fig 2) with undetectable serum Tg level. The submaxilar lymph node was no longer evident.

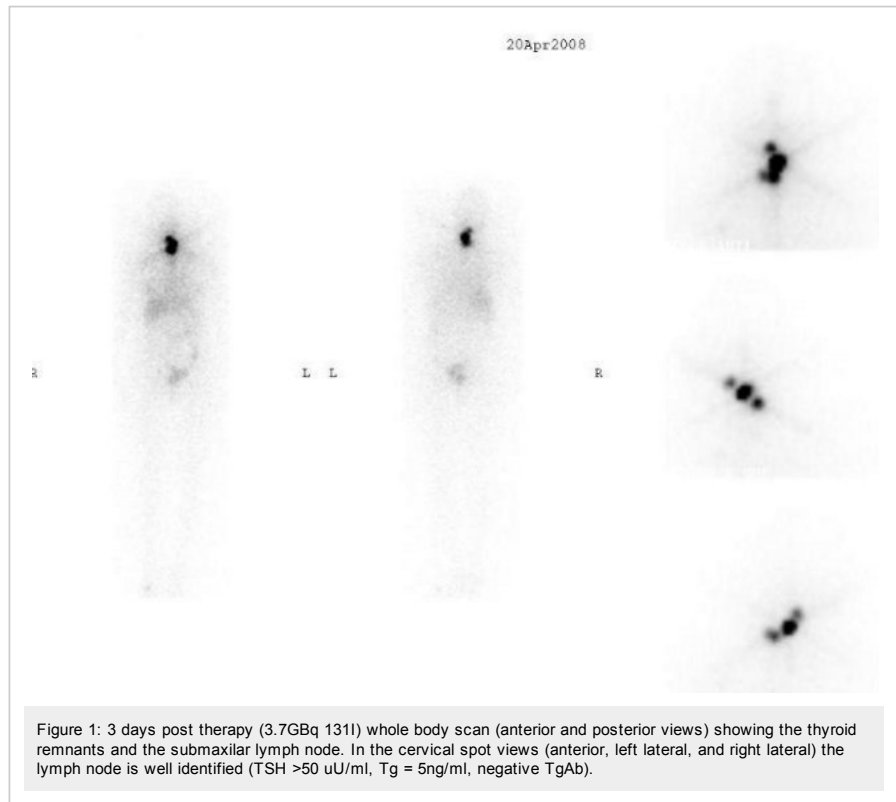


Figure 1: 3 days post therapy (3.7GBq <sup>131</sup>I) whole body scan (anterior and posterior views) showing the thyroid remnants and the submaxilar lymph node. In the cervical spot views (anterior, left lateral, and right lateral) the lymph node is well identified (TSH >50 uU/ml, Tg = 5ng/ml, negative TgAb).

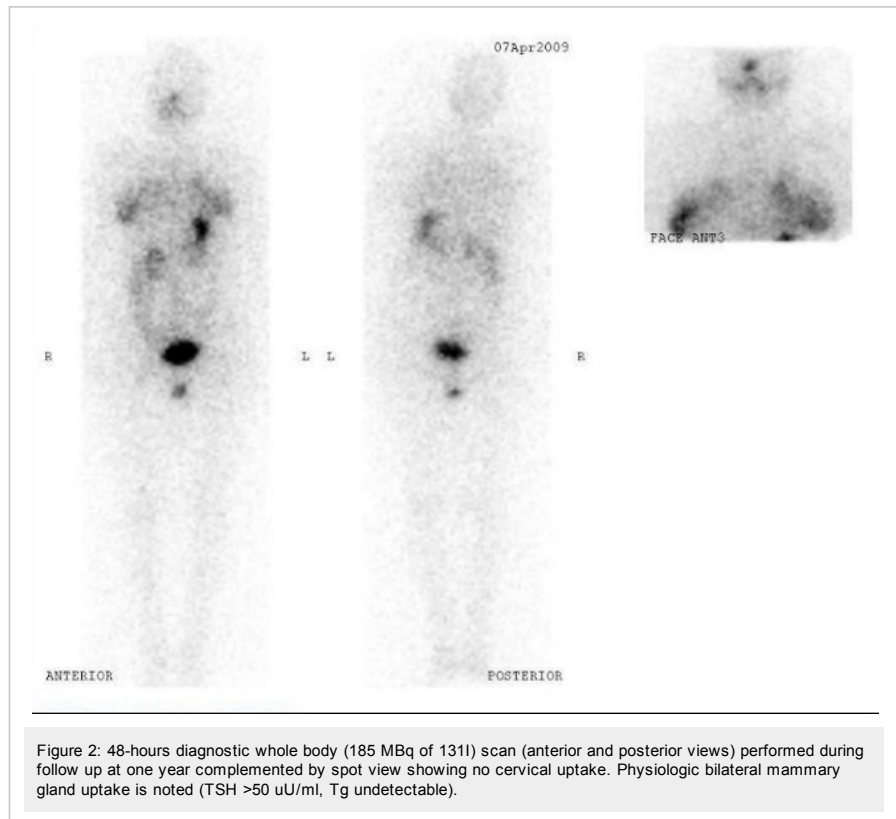


Figure 2: 48-hours diagnostic whole body (185 MBq of <sup>131</sup>I) scan (anterior and posterior views) performed during follow up at one year complemented by spot view showing no cervical uptake. Physiologic bilateral mammary gland uptake is noted (TSH >50 uU/ml, Tg undetectable).

## Discussion

Thyroglossal cysts are common abnormalities of thyroid development that present as palpable and sometimes symptomatic neck masses. These are benign fibrous cysts that form from a persistent thyroglossal duct occurring more frequently in young patients but are also common at adult age. Very rarely, the persistent duct tissue becomes malignant and is called thyroglossal duct cyst carcinoma (or TDC carcinoma). It is accepted that the carcinoma arises from thyroglossal thyroid ectopic tissue<sup>(4)</sup>. This theory is based on the fact that most cases of TDC carcinoma are solitary and non concomitant with thyroid gland carcinoma<sup>(5)</sup>. There are no reports suggesting that malignancy in TDC could be linked with previous cervical irradiation<sup>(6)</sup>.

The clinical presentation of TDC carcinoma may be indistinguishable from that of benign TDCs, however thyroglossal duct carcinoma may present as a rapidly enlarging neck mass. The tumor can be located anywhere along the course of the thyroglossal duct, however the majority are found below the level of the hyoid bone<sup>(1,4,7)</sup>. Papillary carcinoma is the most frequent histological type (more than 75%) arising in a TDC and it is seen most frequently in young women with a female:male ratio of 1.5:1<sup>(8)</sup>. Other types - although more rare - include follicular variant of papillary carcinoma and pure follicular carcinoma; squamous and anaplastic carcinomas have also been reported<sup>(9)</sup>.

TDC carcinoma was first described in 1915<sup>(10)</sup> and since then many cases have been reported, most of them non concomitant with thyroid gland carcinoma and without lymph node metastases. In the reported cases of TDC carcinoma with regional lymph node metastases, TDC carcinoma was rather concurrent with thyroid gland carcinoma<sup>(3)</sup>. In the absence of thyroid malignancy, the association of TDC carcinoma with regional lymph node invasion is exceptional, and even more when the metastases reach multiple lymph node compartments.

This case of TDC carcinoma has classical findings: a young woman who presented a relatively slow enlargement of a middle cervical mass, concurrent with a small cervical lymph node found by US. The low accuracy and questionable use of the preoperative fine needle aspiration biopsy (FNAB) of the cyst guided by US even by experienced hands<sup>(12)</sup> was confirmed since FNAB findings were non-diagnostic for malignancy. In this case, the pre-operative diagnosis of thyroid carcinoma was not done and the TDC was approached as benign cyst regarding its relatively slow growth. US showed a small lymph node anterior to the jugular vein which was considered probably benign. CT findings showed a central small nodule in the cyst, partially calcified but with no evidence of intramural invasion which is considered by many authors as a sign of malignancy<sup>(13,14)</sup>. Thyroid gland investigations were normal which is usual in most of TDC carcinomas. The cyst was surgically removed by Sistrunk's procedure<sup>(15,16,17)</sup> which is preferred to simple excision and was expected to suffice since the thyroid gland was normal and negative margins had been achieved. Histological analysis of the cyst showed evidence of papillary thyroid carcinoma in three sites of the cyst's walls which expresses an aggressive form of the carcinoma. Two independent, successive readings confirmed the diagnosis of an aggressive TDC carcinoma.

The prognosis of papillary carcinoma arising in a thyroglossal cyst is usually good and similar to that of papillary carcinoma of the thyroid gland, with cure rates above 95%<sup>(6,15)</sup>. Study of proto oncogenes RET and specific RET have not been done. However, to reach such highest rate of success thyroglossal duct carcinoma appropriate investigation and treatment are needed, and usually the controversial question of total thyroidectomy and its potential preventive impact arises<sup>(6,15,16,17)</sup>. This was also the case in this young woman, but the presence of cancer in multiple sites of the cyst and the lymph node found by US were considered decisive for the choice of total thyroidectomy combined with cervical lymphadenectomy. This decision was appropriate since histological results showed two metastatic lymph nodes with absence of thyroid gland carcinoma (histological features of the removed total thyroid gland were normal after two separate readings done in two different pathology departments). Both metastatic lymph nodes belonged to the same anterior jugular compartment. Therefore, the use of radioiodine therapy was obvious because of the evidence of lymphatic invasion. In case of total thyroidectomy, a post operative dose of 3.7 GBq is recommended to complete the treatment course of the TDC carcinoma, mainly in case of macroscopic suspicion or histological evidence of local invasion. Surprisingly, the post therapy <sup>131</sup>I scan showed - in addition to the thyroid remnants - another site of uptake located in medium submaxilar region. This uptake corresponded to a submaxilar lymph node which was clinically palpable and initially considered as inflammatory, reactive to dental infection. In total, three lymph nodes belonging to two different lymphatic compartments: the jugular anterior and the submaxilar were invaded.

This clinical observation points out the aggressive form of this carcinoma and highlights the need of extensive treatment. Regarding the TNM classification, this patient under 45 years with TN<sub>1</sub>M<sub>0</sub><sup>(18,19)</sup> should be on stage one. However and despite the fact that the thyroid gland was normal, the TDC carcinoma was associated with three involved lymph nodes which suggested a real dissemination of disease locally. The presence of metastases express an aggressive form of TDC carcinoma and should suggest the same therapeutic strategy and follow up than a patient in a stage II. The post operative therapeutic strategy should be based on a suppressive thyroxin doses (TSH <0.1uU/ml) rather than a substitutive therapy and include systematic radioiodine therapy until negative whole body scan is reached as well as undetectable plasmatic thyroglobulin level. For this patient, the first dose of <sup>131</sup>I was successful and negative diagnostic whole body scan and undetectable thyroglobulin were obtained during the first year of the follow up. Moreover, the size of the involved submaxilar node was significantly reduced and confirmed by negative cervical US. The indication of a submaxilar lymphadenectomy is still discussed but not yet adopted for this patient. However, rigorous follow up and adequate suppressive therapy will be maintained during 5 years to allow appropriate therapeutic effect and to avoid clinical events. Further, therapeutic strategy should be adjusted regarding the output of the follow up at 5 years.

### Conclusion

Thyroid carcinoma arising in a TDC is usually developed within the cyst and therefore its efficient treatment is based on surgery alone by Sistrunk's procedure. However, complete investigation is needed for properly staging since some variants, although rare, may exist showing aggressive loco-regional behaviour. When evidence of aggressiveness is noted, thyroglossal duct carcinoma needs extensive therapy including total thyroidectomy whatever the status of the thyroid gland, followed by an ablative dose of iodine-131. The role of <sup>131</sup>I is essential because it will treat thyroid tissue remnants or lymph metastasis, make appropriate staging, and allow adequate follow up.

### References

1. Allard RH. The thyroglossal cyst. *Head Neck Surg* 1982;5:134-146. [Volver](#).
2. Van Vuuren PA, Balm AJ, Gregor RT, Hilgers FJ, Loftus BM, Delprat CC et al. Carcinoma arising in thyroglossal remnants. *Clin Otolaryngol* 1994; 19:509-515. [Volver](#).
3. Heshmati HM, Fatourehchi V, van Heerden JA, Hay ID, Goellner JR. Thyroglossal duct carcinoma: report of 12 cases. *Mayo Clin Proc* 1997;72:315-319. [Volver](#).
4. Patten B. *Human Embryology*. 3<sup>rd</sup> Ed. New York: McGraw-Hill Book Co; 1968: 441-442. [Volver](#).
5. Al-Dousary S. Current management of thyroglossal-duct remnant. *J Otolaryngol* 1997; 26:259-26. [Volver](#).
6. Mazzaferrri EL. Thyroid cancer in Thyroglossal duct remnants: A diagnostic and therapeutic dilemma. *Thyroid*; 2004; 14(5):335-336. [Volver](#).
7. Todd, NW. Common congenital anomalies of the neck. *Embryology and surgical anatomy*. *Surg Clin North Am* 1993;73:599-610. [Volver](#).
8. Walton BR, Koch KE. Presentation and management of a thyroglossal duct cyst with a papillary carcinoma. *South Med J* 1997;90: 758-776. [Volver](#).
9. Fernandez JF, Ordopez NG, Schultz PN, Samaan NA, Hickey RC. Thyroglossal duct carcinoma. *Surgery* 1991;110:928-935. [Volver](#).
10. Hilger AW, Thompson SD, Smallman LA, Watkinson JC. Papillary carcinoma arising in a thyroglossal duct cyst: a case report and literature review. *J Laryngol Otol* 1995;109: 1124-1127. [Volver](#).
11. Kristensen S, Juul A, Morsener J. Thyroglossal cyst carcinoma. *J Laryngol Otol* 1984; 98:1277-1280. [Volver](#).
12. Solbati L, Cioffi V, Ballatari E. Ultrasonography of the Neck. *Rad Clin North Am* 1992;30:941-955. [Volver](#).
13. Glastonbury CM, Davidson HC, Haller JR, Harnsberger HR. The CT and MR imaging features of carcinoma arising in thyroglossal duct remnants. *AJNR Am J Neuroradiol*. 2000;21:770-774. [Volver](#).
14. Reede DL, Bergeron RT, Som PM. CT of thyroglossal duct cysts. *Radiology* 1985; 157:121.-125. [Volver](#).
15. Aluffi P, Pino M, Boldorini R, Pia F. Papillary thyroid carcinoma identified after Sistrunk procedure: report of cases and review of the literature. *Tumori*. 2003;89:207-210. [Volver](#).
16. Brousseau VJ, Solares CA, Xu M, Krakovitz P, Koltai PJ. Thyroglossal duct cysts: Presentation and management in children versus adults. *Int J Pediatr Otorhinolaryngol* 2003;67:1285-1290. [Volver](#).
17. Kennedy TL, Whitaker M, Wadih G. Thyroglossal duct carcinoma: a rational approach to management. *Laryngoscope* 1998;108:1154-1155. [Volver](#).
18. Shaha AR. TNM classification of thyroid carcinoma. *World J Surg*. 2007 May;3; 5:879-887. [Volver](#).
19. Nobuyuki W, Hirotsuka N, Nobuyasu S, Yoshihiko M, Yasushi R, Munetaka M et al. Prognostic value of the 6th edition AJCC/UICC TNM classification for differentiated thyroid carcinoma with extrathyroid extension. *J Clin Endocrinol Metab*. 2007 Jan;92: 1:215-2180. [Volver](#).



Esta obra está bajo una licencia de Creative Commons

© 2010 Alasbimn Journal